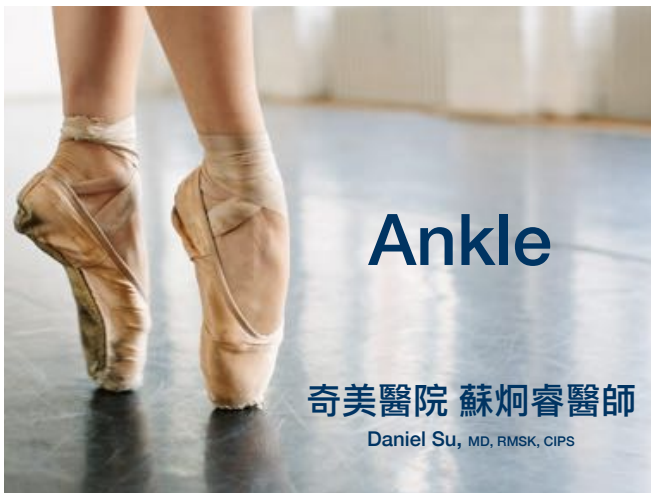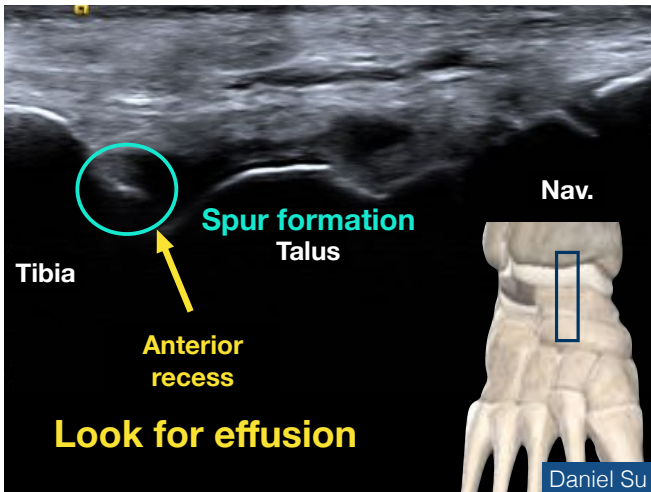




### Regions

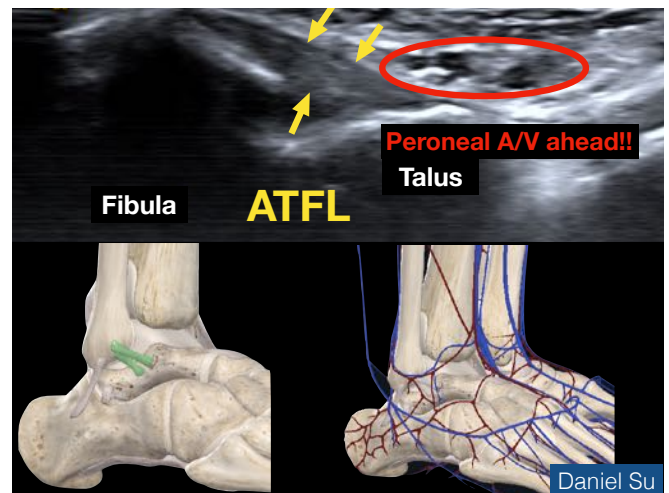
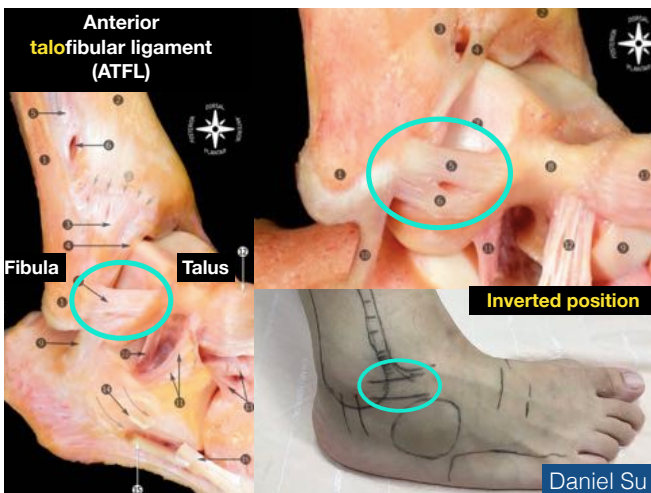
- Anterior: **Anterior recess**
- Medial: Deltoid ligament, **Tarsal tunnel structures**, Spring ligament
- Lateral: **ATFL, AITFL, CFL**
- Posterior: PTFL, **Achilles tendon**
- Sole: **Plantar fascia**

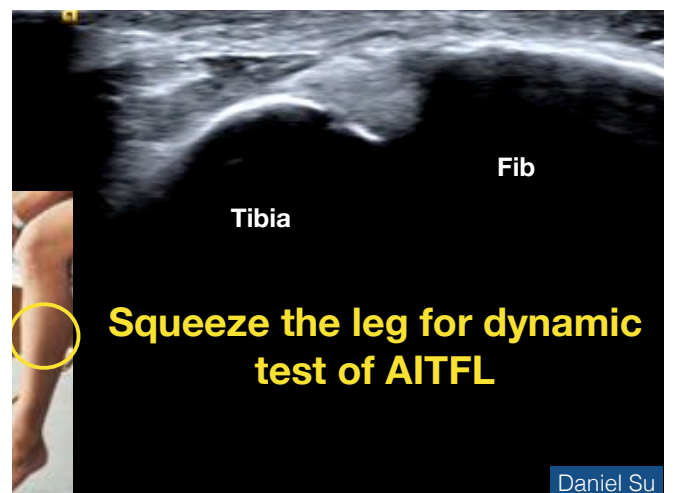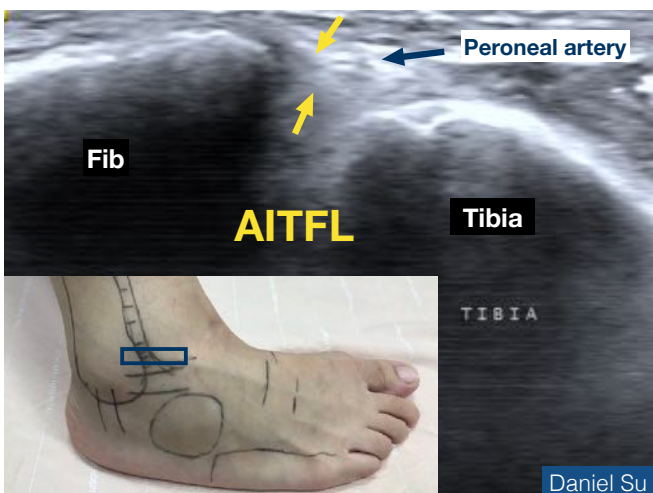
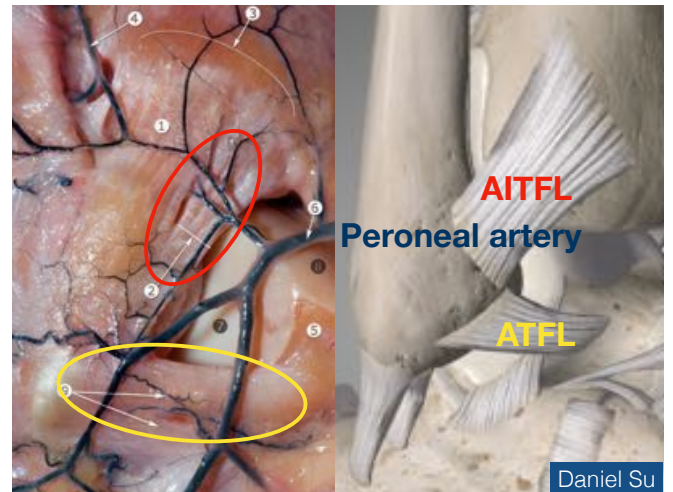
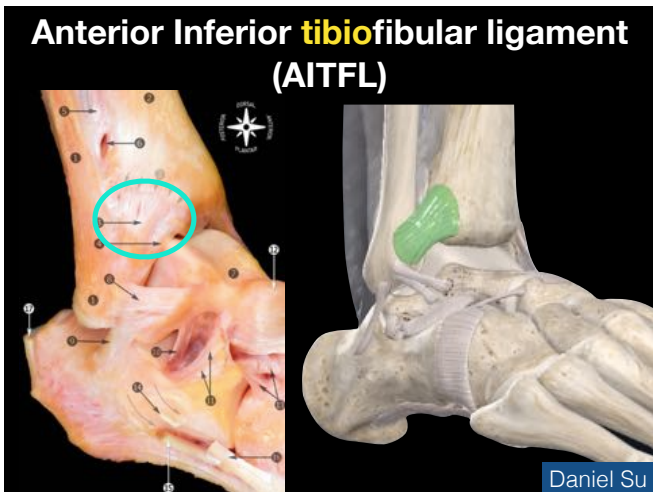
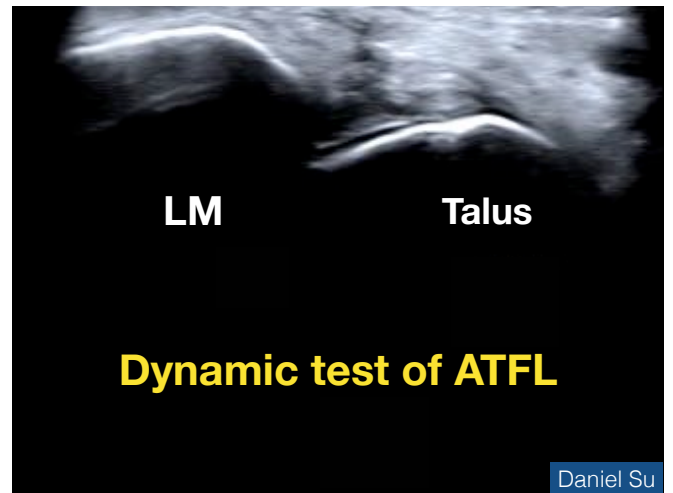
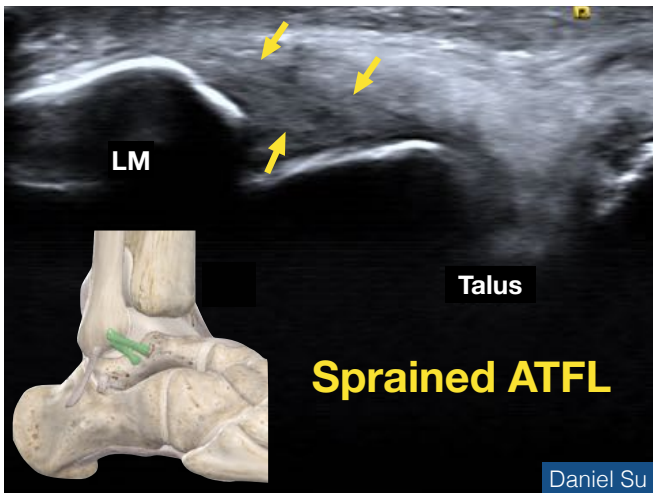
Daniel Su

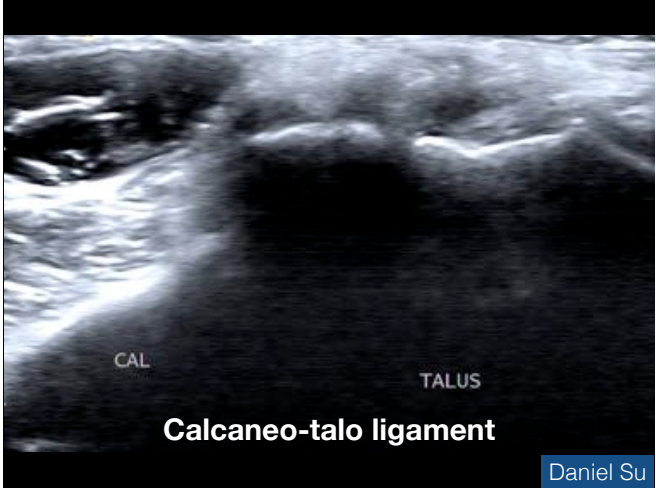
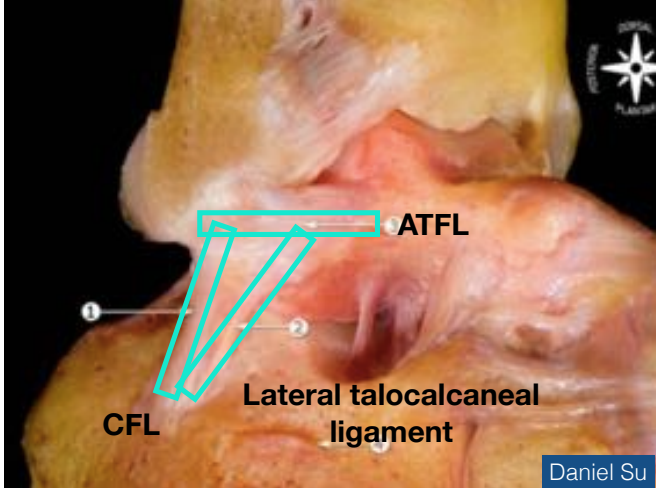
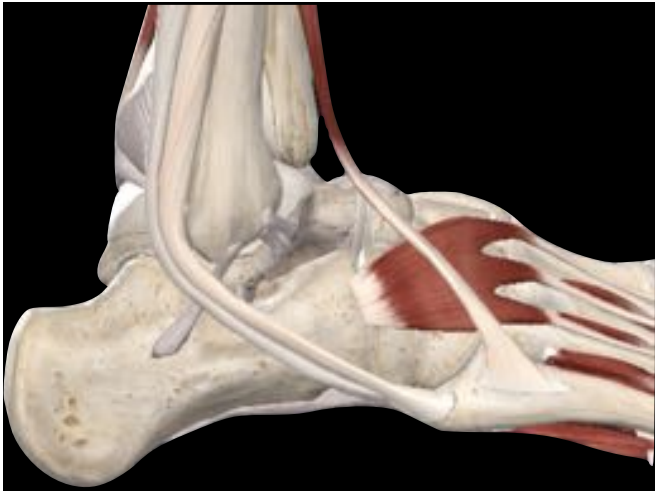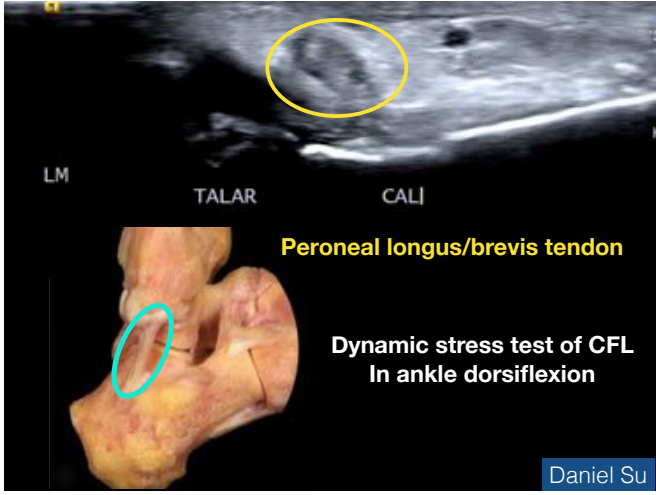
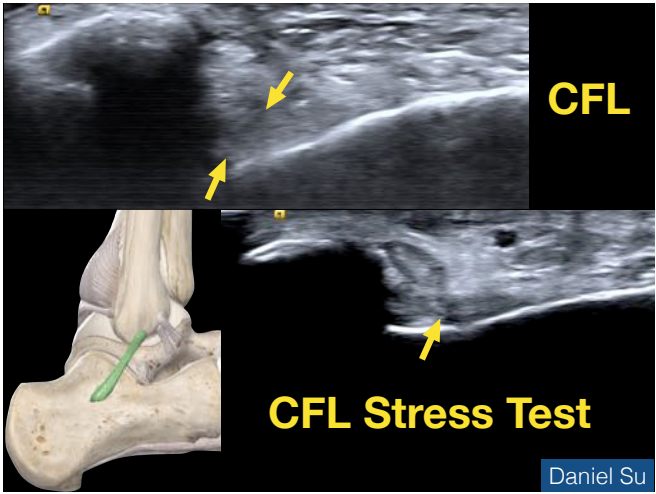
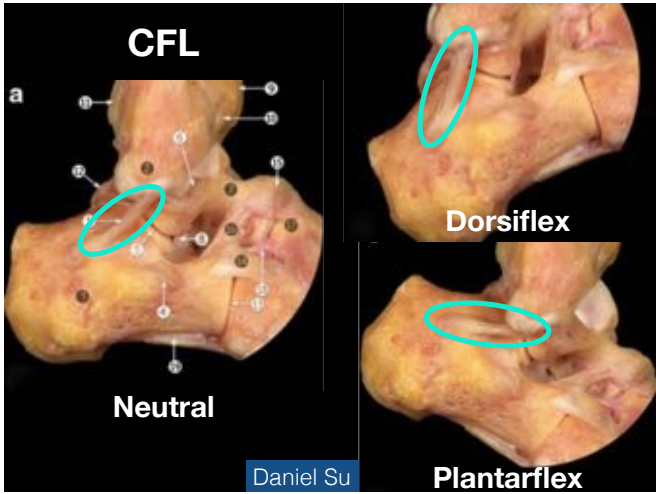


### Lateral region: ATFL, AITFL, CFL

Daniel Su

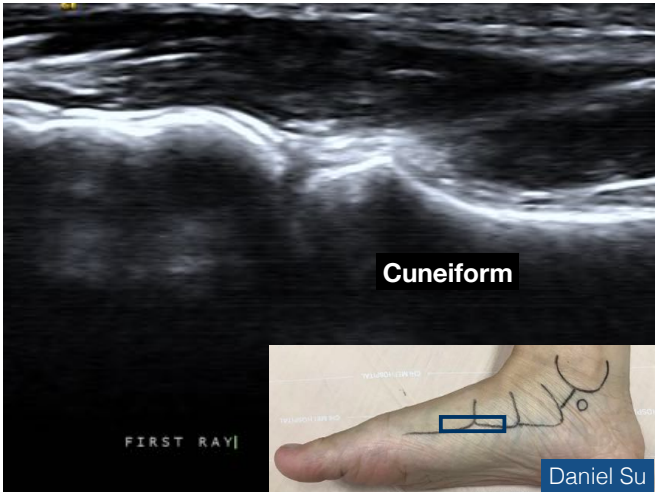
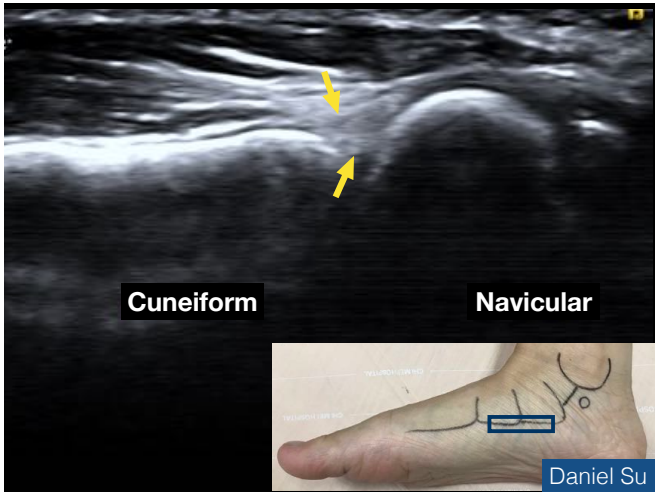
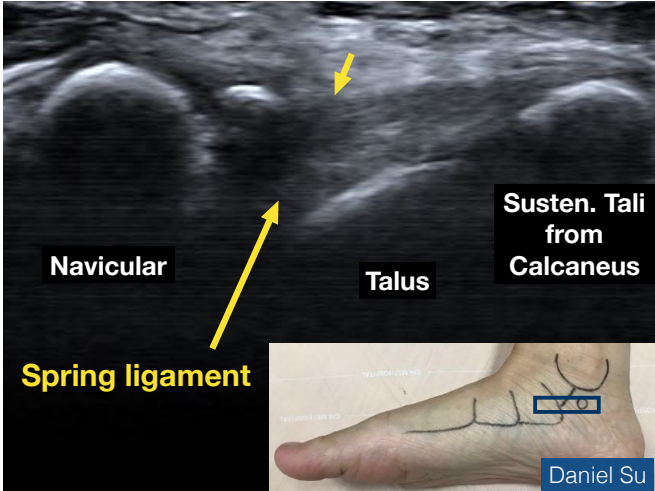
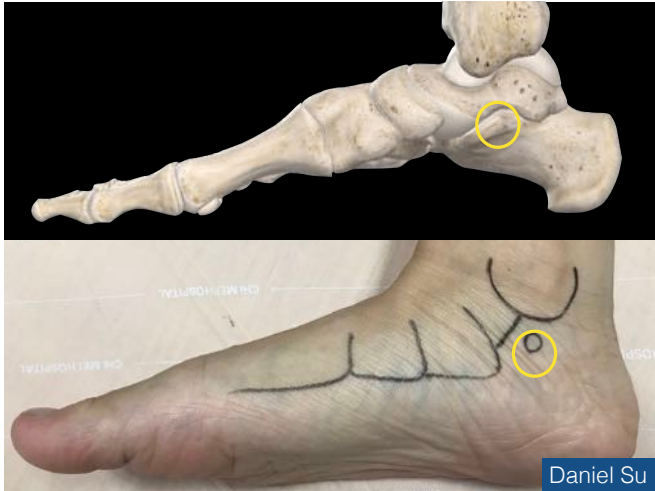
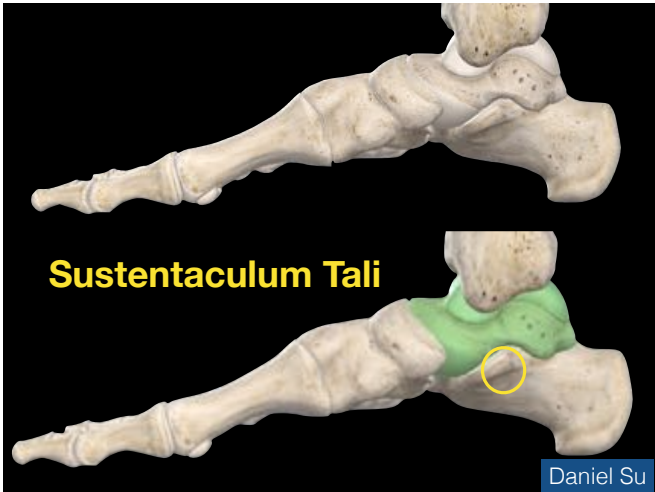


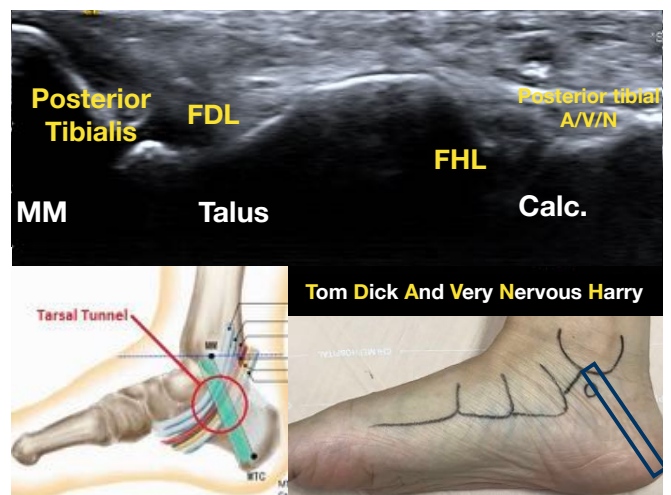
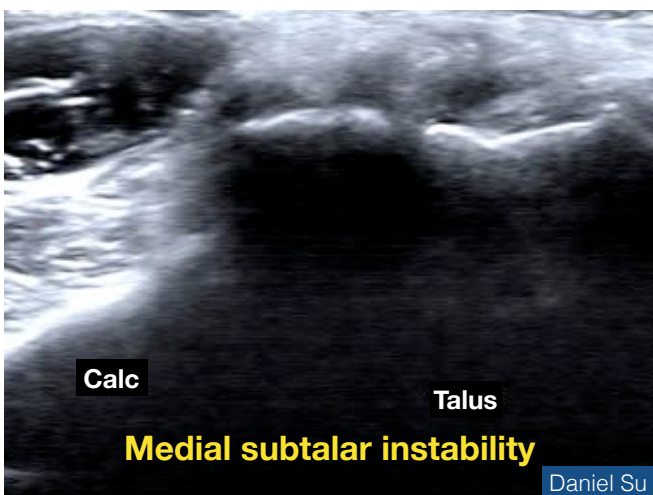
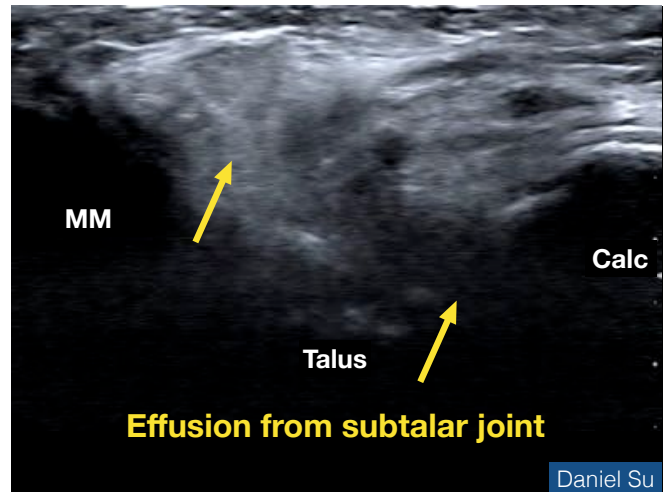
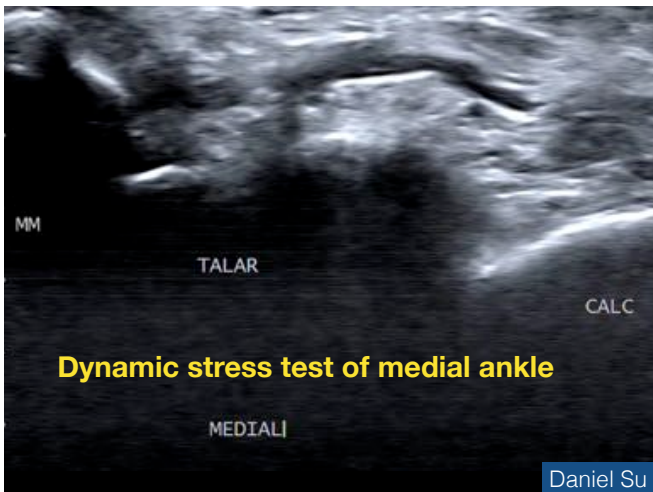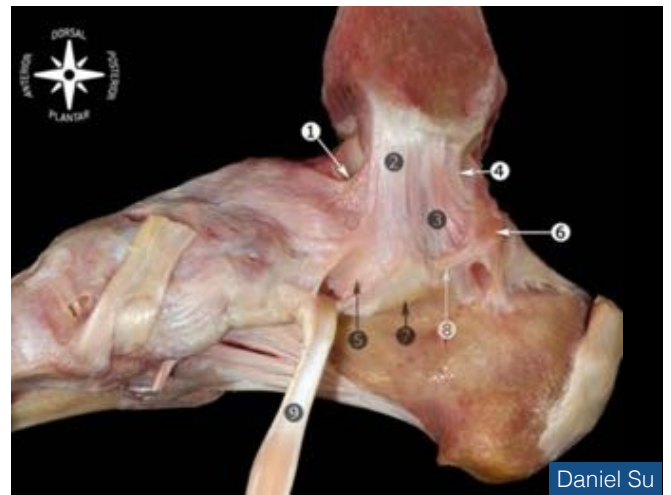
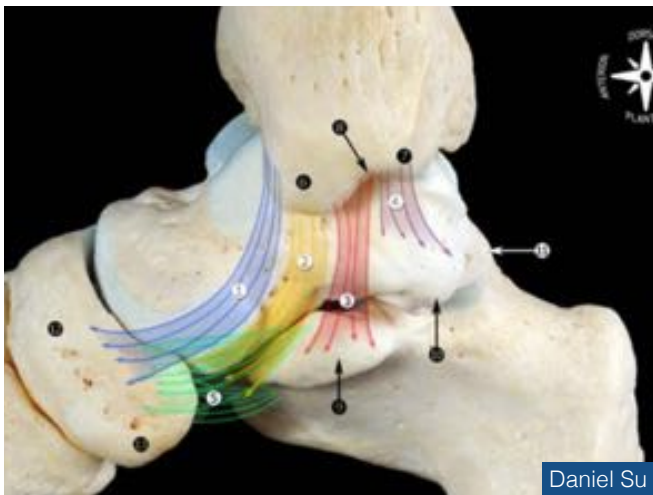




Medial: Deltoid ligament, Tarsal tunnel, Spring ligament

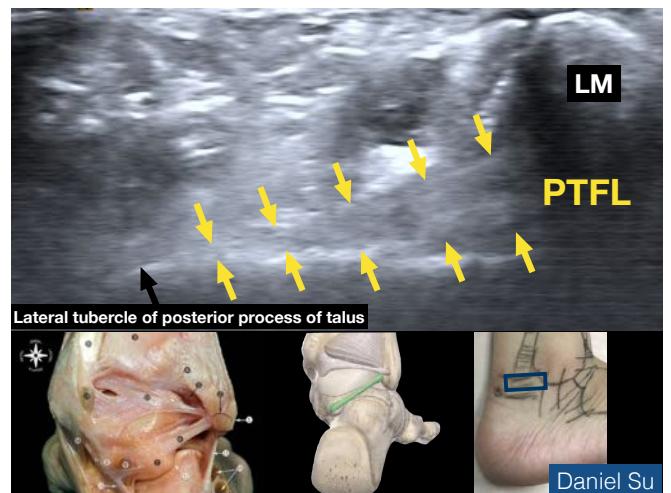
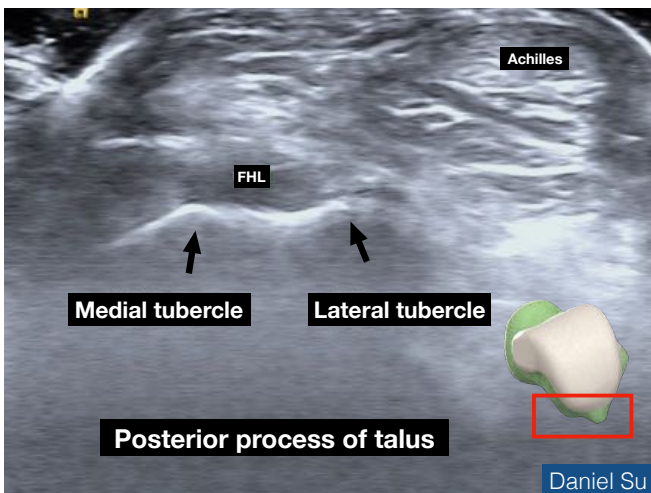
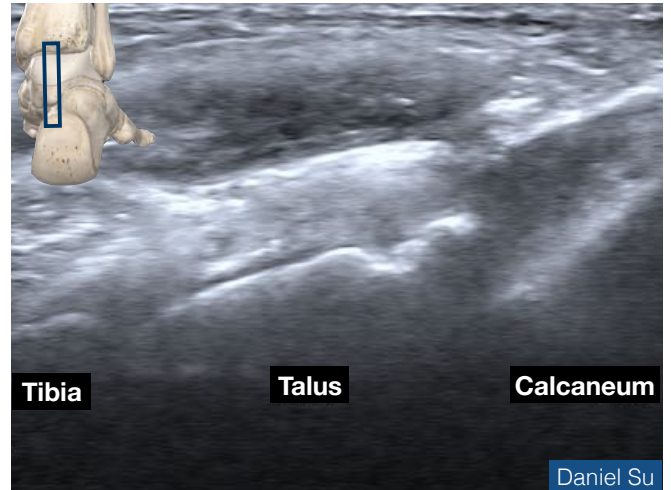
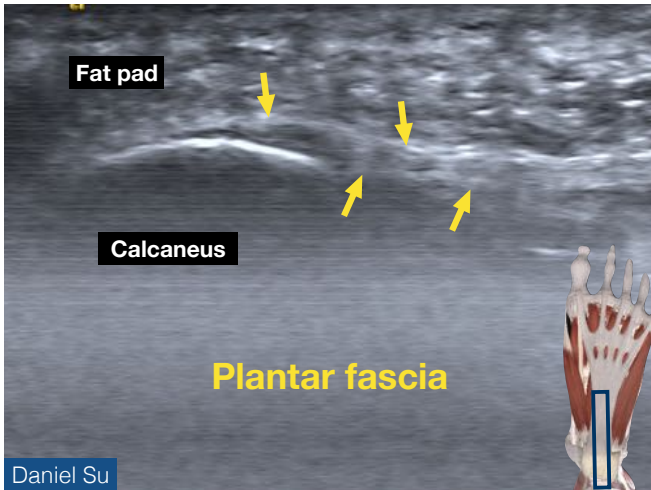
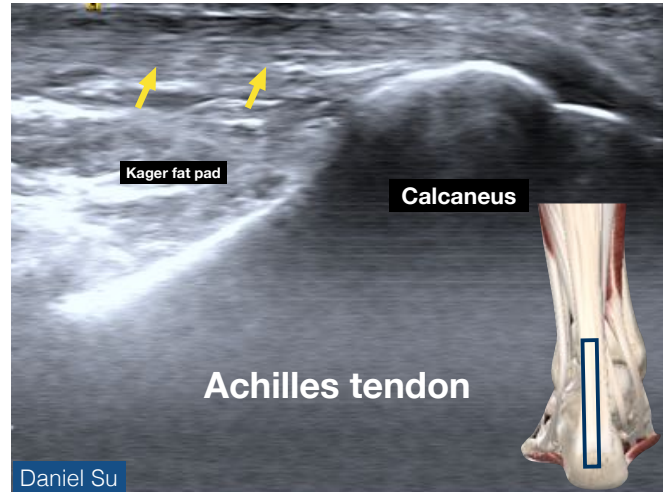
Daniel Su





Posterior: PTFL, Achilles tendon

Daniel Su



## Step by step

- Anterior: **Anterior recess**
- Medial: Deltoid ligament, **Tarsal tunnel structures**, Spring ligament
- Lateral: **ATFL, AITFL, CFL**
- Posterior: PTFL, **Achilles tendon**
- Sole: **Plantar fascia**

Daniel Su

## Thanks for your time!

奇美醫院 蘇炯睿

Daniel Su, MD, RMSK, CIPS

[dr.daniel@gmail.com](mailto:dr.daniel@gmail.com)

<http://prolostudio.blogspot.com>

